

An Approach in the Diagnosis of Alzheimer Disease - A Survey

Bhagya shree S. R*¹, Dr. H. S. Sheshadri*²

Department of Electronics and Communication Engineering, ATME College of Engineering, Mysore- 570023, India.

Department of Electronics and communication Engineering, People's Educational Society College of Engineering, Mandya-571401, India

Abstract- The detection and characterization of cognitive deficits associated with age-related neurodegenerative diseases such as Alzheimer's disease (AD) is the focus of growing clinical research interest as increasing numbers of people survive into older age. There is a need to accurately detect the cognitive changes that signal the beginning of a progressive dementia syndrome and to differentiate among relative disorders [1]. In US according to National Center for Health Statistics of the centers for disease control & prevention 83,495 people have died because of Alzheimer` disease.[2]. The timely diagnosis & treatment may help the common man to have a better life. In this paper we are going to discuss about the various techniques that are used in diagnosis.

Keywords- Alzheimer`s disease, cognitive

I.INTRODUCTION

There are various neuro related disorders which reduce the quality of human life. Dementia is one such disorder. Dementia takes its roots from Latin, where 'de' means 'apart' and 'mentis' means 'mind'. Dementia is the disease of the brain causing loss of cognitive functions (reasoning, memory and other mental abilities) due to trauma or normal ageing.

Fig.1 shows the number of people affected by AD at different time intervals.[3]. From the figure it is clear that there a great scope for diagnosis of Alzheimer`s disease at early stages.

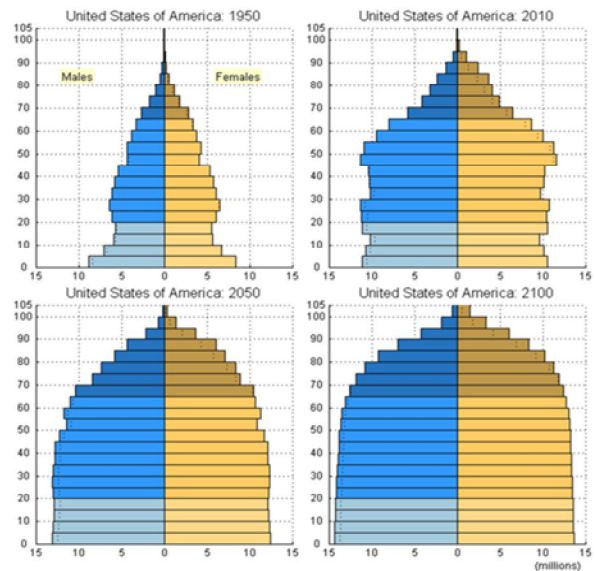


Fig1. Chart of number of people affected by Alzheimer`s disease.

II.LITERATURE SURVEY

- Dementia is further classified into
- Alzheimer` disease: Abnormalities are deposits of the protein fragment beta-amyloid & twisted strands of the protein tangles.
- Parkinson`s disease: The abnormality in this disease is abnormal deposits of the protein alpha-synuclein inside nerve cells in the brain.
- Creutzfeldt-Jakob disease : Inability is caused by the folding of prior protein throughout the brain.
- Normal Pressure Hydrocephalus: This is caused by the buildup of fluids in brain.

- Dementia with Lewy Bodies: Abnormal deposits of the protein inside the nerve cells in the brain.
- Vascular Dementia: Impairment is caused by decreased blood flow to parts of the brain.
- Front temporal Dementia: involves damage to brain cells, especially in the front and side regions of brain.

Alzheimer’s disease accounts for 60-80% of dementia. If the disease is not diagnosed at the initial stage the severity of the disease increases. There are various risk factors which contribute to the development of the disease.

- Age
- Genetics
- Smoking and Alcohol Intake
- Cholesterol.
- Down Syndrome[4]

The symptoms of Alzheimer` diseases are

- Decision-making—unable to make any decision.
- Poor judgment—Unable to react in emergencies.
- Misplacing things—Increased disorientation and confusion, even in familiar surroundings.
- Impairment of movements—Difficulty in walking and other movements such as swallowing, which increases the risk of malnutrition and choking.
- Verbal communication—Unable to remember simple words and substitute some irrelevant words in their speech. This makes it difficult for the listener to understand.
- Abnormal moods—this includes anxiety and depression.
- Complete loss of memory—unable to recognize even close relatives and friends.

Whenever these symptoms are observed the patient has to be tested in three different stages[5].

- General checkup:
- A physical examination
- A review of the medication the patient is taking in relation with symptoms
- A range of tests, including blood tests, to rule out other possible causes of symptoms, such as a vitamin B deficiency

III. PSYCHOLOGICAL TESTS

There are some questionnaires that can be used to help to test the mental abilities and to test the severity. The different neuropsychological tests conducted for diagnosis of AD and their comparison is given in Table1.

| Instrument | Reliable | Practical | Valid |
|----------------------------|----------|-----------|-------|
| MMSE ^b | +++ | +++ | +++ |
| BIMC ^c | +++ | +++ | +++ |
| ADAS-Cog ^d | +++ | ++ | +++ |
| SKT ^e | +++ | ++ | ++ |
| Mattis dermentia scale | ++ | + | ++ |
| CERAD Battery ^f | +++ | ++ | +++ |
| NYU Battery | +++ | +++ | + |

TABLE 1: COMPARISON OF VARIOUS NEUROPSYCHOLOGICAL TESTS

+ = satisfied to slight

++ = moderate

+++ = high degree

Mr.Subramani Mani has done a comparison of cross cultural population using machine learning. But the sample size is very small [n=114][6]

IV. BRAIN SCANS

Brain scans are essential for diagnosing dementia. They are needed to check for evidence of other possible problems that could explain a person’s symptoms, such as major stroke or a brain tumor.

Several types of brain scan can be used to help diagnose dementia. These are outlined below.

1. Computerized tomography (CT) scan:

A computerized tomography (CT) scan can be used to check for signs of stroke or a brain tumor.

A CT scan cannot provide detailed information about the structure of the brain.

2. Magnetic resonance imaging (MRI)

The National Institute for Health and Clinical Excellence (NICE) recommends using a magnetic resonance imaging (MRI) scan to help confirm a diagnosis of dementia.

An MRI scan can provide detailed information about the blood vessel damage that occurs in vascular dementia, plus any shrinking of the brain (atrophy). In Alzheimer's disease, the whole brain is susceptible to shrinking, which could be well diagnosed using MRI. [7]

V. OTHER SCANS AND PROCEDURES

Other types of scan, such as a single photon-emission computed tomography (SPECT) scan, or a positron emission tomography (PET) scan, may be recommended if the result of your CT or MRI scan is uncertain. These scans look at how the brain functions and can pick up abnormalities with the blood flow in the brain.

Dr. K.D. Desai, Prof. Sonal Parmar in their paper Effective early detection of Alzheimer's and Dementia disease using Brain MRI Scan Images [7] is very useful in the detection of AD.

Marilyn Albert and team a neuro imaging work group working for Alzheimer's association says that Structural MRI has been extensively used to characterize the changes in normal aging, mild cognitive impairment, AD, and other dementias. MRI measures of brain volume, especially medial temporal lobe structures, are expected to be useful surrogates for measuring treatments that slow progression of neuro degeneration in AD. [8]

VI. CONCLUSION AND FUTURE WORK

The techniques which are discussed in the psychological tests are limited for a particular group of people. In the future the authors are planning to take up several new approaches for an early detection of **Alzheimer` disease**. This paper is an overview of

the biomedical aspects of such diseases and a bird's eye view to take up challenges in the application of imaging modalities for early detection.

In the future we are planning to take up a new approach which is applicable for the people belonging to different age, sex, culture and education. This is a suggested method in 10/66 dementia group.

ACKNOWLEDGMENT

We are thankful to Dr.H.S Sheshadri and my research colleagues who supported with their data in respect of the **Alzheimer` diseases** .

REFERENCE

- [1] David P. Salmon¹ and Mark W. Bondi^{2,3} "Neuropsychological Assessment of Dementia" *Access NIH public, PubMed central, US national library of medicine National Institutes of Health, May 2010.
- [2]. Alzheimer's Association, 2013 Alzheimer's Disease Facts and Figures, Alzheimer's & Dementia, Volume 9, Issue 2
- [3]. <http://aging.senate.gov/reports/rpt2012.pdf> .
- [4]. <http://alzheimers.emedtv.com/dementia/dementia-risk-factors.html>
- [5]. Michael saling, Associate Professor ,Henry Brodaty Professor ,Dr Mark Yates , Dr Sam Scherer, Professor Kaarin Anstey,(2007), Early Diagnosis of Dementia
- [6] Subramani Mani^{1,3,5}, Malcolm B. Dick^{2,3}, Michael J.Pazzani^{1,3}, Evelyn L. Teng⁴, Daniel [7]. Dr. K.D. Desai¹, Prof. Sonal Parmar² Effective early detection of Alzheimer's and Dementia disease using Brain MRI Scan Images International Journal of Emerging Technology and Advanced Engineering (ISSN 2250-2459, Volume 2, Issue 4, April 2012)
- [8]. Marilyn Albert, PhD^a; Charles DeCarli, MD^b; Steven DeKosky, MD^c; Mony de Leon, EdD^d; Norman L. Foster, MD^e; Nick Fox, MD^f; Richard Frank, MD, PhD^g; Richard Frackowiak, PhD^e; Clifford Jack, MD^h; William J. Jagust, MD^{b,i}; David Knopman, MD^h; John C. Morris, MD^j; Ronald C. Petersen, MD, PhD^h; Eric Reiman, MD^k; Philip Scheltens, MD, PhD^l; Gary Small, MD^m; Hilkka Soininen, MD, PhDⁿ; Leon Thal, MD^o; Lars-Olof Wahlund, PhD^p; William Thies, PhD^q; Michael W. Weiner, MD^{r,s} (Chair); and Zaven Khachaturian, Ph.D. (Secretariat), The Use of MRI and PET for Clinical Diagnosis of Dementia and Investigation of Cognitive Impairment: A Consensus Report